

## CASE REPORT



### OPEN ACCESS

**Received:** 28-11-2020

**Accepted:** 11-12-2020

**Published:** 21-12-2020

**Citation:** Geetha HH, Gurupriya S, Nazma S, Anusha B, Zeba K. (2020). Primary spontaneous complete colporrhexis following vaginal delivery — A rare case. International Journal of Preclinical & Clinical Research. 1(1): 39-41. <https://doi.org/10.51131/IJPCCR/v1i1.4>

\* **Corresponding author.**

[geethahh96@gmail.com](mailto:geethahh96@gmail.com)

**Funding:** None

**Competing Interests:** None

**Copyright:** © 2020 Geetha et al. This is an open access article distributed under the terms of the [Creative Commons Attribution License](https://creativecommons.org/licenses/by/4.0/), which permits unrestricted use, distribution, and reproduction in any medium, provided the original author and source are credited.

Published By Basaveshwara Medical College & Hospital, Chitradurga, Karnataka

### ISSN

Print: XXXX-XXXX

Electronic: XXXX-XXXX

## Primary spontaneous complete colporrhexis following vaginal delivery — A rare case

**H H Geetha<sup>1\*</sup>, S Gurupriya<sup>2</sup>, Shamim Nazma<sup>2</sup>, B Anusha<sup>3</sup>, Khaleel Zeba<sup>3</sup>**

<sup>1</sup> Professor and HOD, Department of OBG, BMCH & RC, Chitradurga, Karnataka, India

<sup>2</sup> Assistant professor, Department of OBG, BMCH & RC, Chitradurga, Karnataka, India

<sup>3</sup> Postgraduate, Department of OBG, BMCH & RC, Chitradurga, Karnataka, India

## Abstract

Spontaneous trauma to the genital tract during vaginal delivery without instrumentation is very rare. Colporrhexis- rupture of vaginal vault is a very rare type of genital tract injury. A 31 year's woman P2L2 with a previous one left ectopic pregnancy was referred to our institute within one hour of vaginal delivery as a case of suspected rupture uterus. On Per speculum examination under anaesthesia revealed protrusion of the omentum and intestine into the vagina, colporrhexis of the posterior vaginal wall was suspected which could not be repaired vaginally hence proceeded with laparotomy. Opening the abdomen revealed injury of the small intestine also. Total abdominal hysterectomy with the repair of colporrhexis with small bowel resection and anastomosis with temporary ileostomy done. Colporrhexis - a dreadful complication, known to occur both in non-pregnant and pregnant state. It is subdivided into primary or secondary, spontaneous or traumatic, complete or incomplete. We encountered a case of vaginal delivery which had resulted in primary spontaneous complete posterior colporrhexis with small bowel injury

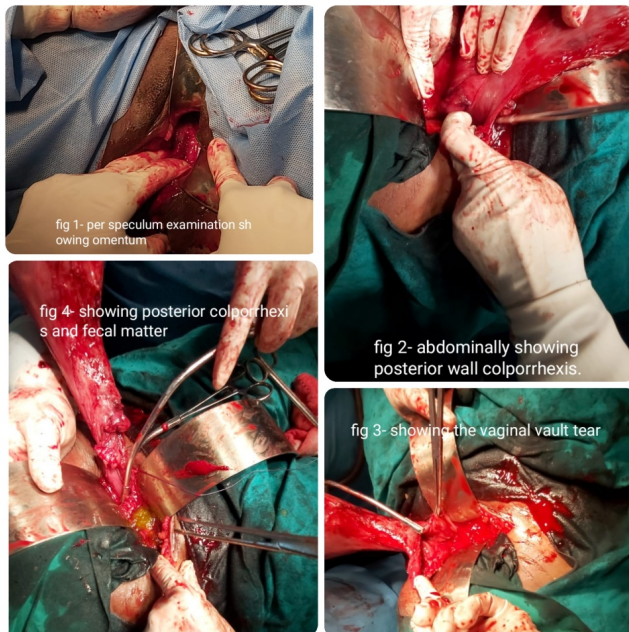
## Introduction

Colporrhexis — rupture of the vaginal vault, a laceration causing separation of the cervix from vaginal fornix, is a very rare type of genital tract injury.<sup>(1)</sup> Spontaneous trauma to the genital tract during vaginal delivery without instrumentation is very rare.<sup>(1)</sup> It can be life-threatening and easily missed, with the diagnosis being overlooked.<sup>(2)</sup> It is classified as primary and secondary, complete and incomplete, spontaneous and traumatic. Colporrhexis can occur in both pregnant and non-pregnant women.<sup>(1,3)</sup> In a non-pregnant state, forceful coitus

and foreign bodies are known to cause such injuries. These are more common in an already weakened vagina because of postmenopausal atrophy and previous surgery. Those related to pregnancy mostly occur during labour, spontaneously or due to trauma. In a non-pregnant state, forceful coitus and foreign bodies are known to cause such injuries.<sup>(4)</sup> These are more common in an already weakened vagina because of postmenopausal atrophy and previous surgery.<sup>(3)</sup> Spontaneous colporrhexis occurs from excessive retraction of the uterus pulling the cervix from its

vaginal attachment. The traumatic varieties occur as complications of forceps delivery and manual removal of placenta.

## Case report



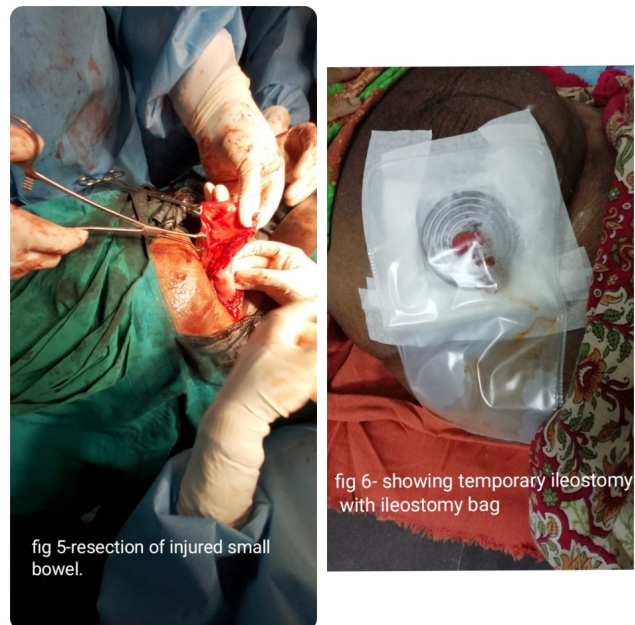A 31 years woman P2L2 with a previous one left tubal ectopic was referred to our institute within one hour of vaginal delivery of full-female baby of weight 2.9 kg at 8:36 pm, as a case of suspected rupture uterus was of 20 to 22 weeks size and flabby. laparotomy. On opening the abdomen fecal matter vaginal vault and small bowel injury suspected.

Peripartum total abdominal hysterectomy with the repair of colporrhexis with small bowel resection and anastomosis with temporary ileostomy done. An abdominal drain was placed and the abdomen was closed. The patient tolerated the procedure well, the intraoperative period and post-operative period was uneventful. Three units of packed cells were transfused in the post-operative period. The abdominal drain was removed on day eight, sutures were removed on day nine and the patient was discharged on day ten. Reversal of ileostomy done after two months.

## Discussion

Colporrhexis-is an unusual and dreadful complication. It is classified as primary and secondary, complete and incomplete, spontaneous and traumatic.<sup>(3)</sup> It is said primary when vaginal vault tear is not associated with uterine extension and secondary when it involves uterine rupture. It could also be

classified as complete tear where the whole vaginal wall is involved including vaginal epithelium, muscularis layer and overlying peritoneum and incomplete where the peritoneum is spared.<sup>(1,3)</sup> Laceration of the upper third of the vagina is rare and generally occurs as a result of rotational forceps.<sup>(4)</sup> Clinical manifestations are similar to the ruptured uterus — sudden cessation of labour pains, followed by continuous pain, vaginal bleeding or signs and symptoms of shock.



Key to management of such lacerations is suture repair, haemostasis, adequate blood and blood product transfusion, and adequate antibiotic coverage. We encountered a case of vaginal delivery that had resulted in primary spontaneous complete posterior colporrhexis with small bowel injury.

The probable cause could be adhesions of previous ectopic repair and weakening of the pouch of Douglas, brutal fundal pressure during the second stage of labor, induction and augmentation of labor with oral misoprostol and oxytocin drip. Literature shows only a few cases of primary colporrhexis have been reported so far.

## Conclusion

Though this type of genital tract injuries is very rare, we should keep in mind that concealed rupture of the vagina and uterus do occur and every woman in labor especially those with a previous history of surgery, should be monitored cautiously so as to diagnose any complications at the earliest to avoid maternal and fetal morbidity and mortality.

## References

- 1) Kabra S, Goyal R, Jain R, Kadam VK. Primary spontaneous complete posterior colporrhexis during labour: a rare case report. *International Journal of Reproduction, Contraception, Obstetrics and Gynecology*. 2016;5(7):2463–2465. doi:10.18203/2320-1770.ijrcog20162152.
- 2) Sakhare AP, Bhanap PL, Mahale AR. Bowel prolapse through colporrhexis - a complication of home delivery. *The Journal of Obstetrics and Gynecology of India*. 2007;57(6):553–554.
- 3) Goyal R, Jain KP, Kabra SL. Primary complete posterior colporrhexis during cesarean section - A case report. *Indian obstetrics and gynaecology. The Journal of Obstetrics and Gynecology of India*. 2017;7(3):18–27.
- 4) Osterling DL, Mccreedy PA, Mcfeejg, Thompson HE. Primary spontaneous colporrhexis. A case report. *Obstet Gynecol*. 1971;38(1):96–104.