

CASE REPORT



Primary cervical extradural Meningioma presenting as neck mass — an unusual presentation of rare case

OPEN ACCESS

Received: 10.04.2021

Accepted: 24.07.2021

Published: 26.07.2021

T Rajesh¹, Darshan Shetty^{2*}

¹ Assistant Professor, Department of Neurosurgery, Mysore Medical College and Research Institute, Mysore, India

² Junior Resident, Department of General Surgery, Mysore Medical College and Research Institute, Mysore, India

Citation: Rajesh T, Shetty D. (2021). Primary cervical extradural Meningioma presenting as neck mass — an unusual presentation of rare case. International Journal of Preclinical & Clinical Research. 2(2): 51-55. <https://doi.org/10.51131/IJPCCR/v2i2.5>

* **Corresponding author.**

darsh.sva@gmail.com

Funding: None

Competing Interests: None

Copyright: © 2021 Rajesh & Shetty. This is an open access article distributed under the terms of the [Creative Commons Attribution License](https://creativecommons.org/licenses/by/4.0/), which permits unrestricted use, distribution, and reproduction in any medium, provided the original author and source are credited.

Published By Basaveshwara Medical College & Hospital, Chitradurga, Karnataka

ISSN

Print: XXXX-XXXX

Electronic: XXXX-XXXX

Abstract

Extradural spinal meningiomas are very rare, especially in cervical region. A purely extradural location presenting as neck mass is quite exceptional reported in this paper. We present a case of extradural meningioma in an 18 year old male located in cervical spine presenting as neck mass that was surgically treated with a provisional diagnosis of schwannoma. Histopathological diagnosis of fibroblastic meningioma was made with the routine hematoxylin and eosin (H & E) stain. The origin, clinical and radiological features, pathological findings with differential diagnosis and surgical treatment are discussed based on review of the literature. A meningioma of extradural in location presenting as neck mass, a rare entity, is still a diagnostic dilemma on clinically and radiology as findings overlap with many other common extradural spinal masses.

Keywords: Extradural; Meningioma; cervical

Introduction

Spinal tumors are classified as either extradural or intradural tumors. Further, intradural tumors can be either intra- or extramedullary in location. Common intradural extramedullary tumors are schwannomas, neurofibromas, and meningiomas while metastases form the bulk of the extradural lesions. Spinal meningiomas are usually intradural in location. Meningiomas account for 25%

to 46% of primary spinal neoplasms, while the incidence of spinal meningiomas is 7.5% to 12.7% of all meningiomas⁽¹⁾. A purely extradural position at cervical spine as reported in this paper is quite exceptional and to the best of our knowledge, only 10 cases have been reported in the literature so far⁽²⁾. Although extremely rare, the possibility of an extradural mass being a meningioma does exist. The case is discussed in this paper for its exceptional location.

Case Report

An 18-year-old male patient presented with swelling in left side of neck since 1 year associated with neck pain and radiating to left upper limb. Patient underwent excision of the swelling in the same site twice in a span of two years. On examination, A solitary swelling measuring 3cm vertical and 5cm horizontal dimension in left posterior cervical triangle, non-tender, firm in consistency, non-mobile, non-pulsatile and scar over swelling noted. Patient had no neurological deficits. Ultrasonography showed soft tissue lobulated homogenous mass lesion well separated from carotid vessels in left mid third of neck -suggestive of peripheral nerve sheath tumor. MRI Cervical spine revealed bilobulated altered signal intensity lesion seen on left side at C4, C5 vertebral levels in Intradural Extramedullary compartment extending to extradural space /adjacent soft tissue widening the neural foramina. Lesion appears hyper intense on T2/STIR, Isointense on T1 and shows intense homogenous contrast enhancement likely peripheral nerve sheath tumor. Based on clinicroadiological diagnosis C4-C5 laminectomy with a provisional diagnosis of schwannoma and intraoperatively tumor was totally extradural adherent to C5 nerve root and internal decompression of tumor with mobilisation and partial excision of tumor with capsule done. By anterior approach near total decompression of tumor with C4C5C6 fusion with PEEK cages and fixation using plates and screws done. The specimen sent to histopathology laboratory and smears showed fibroblastic meningioma and WHO Grade1 was made. The patient showed marked improvement in symptoms and follow up showed sustained improvement.

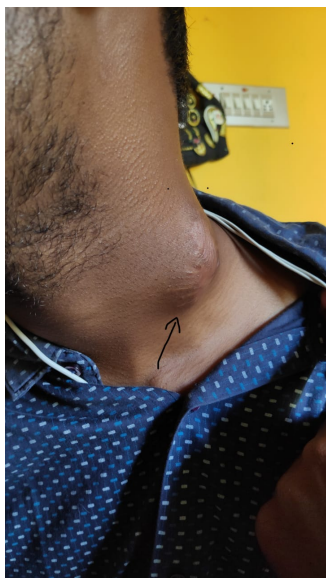

Fig 1. Pre-operative neck swelling

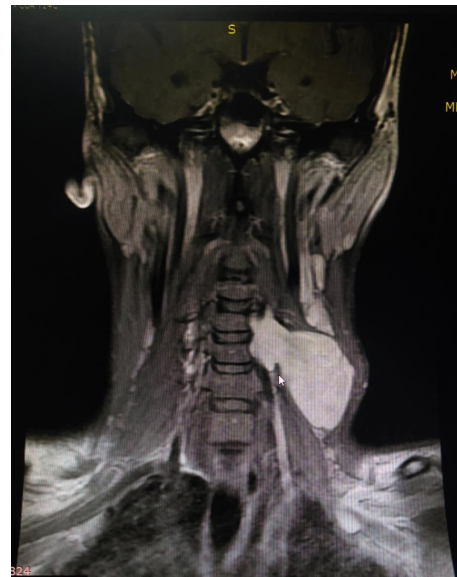

Fig 2. Coronal section of MRI Image

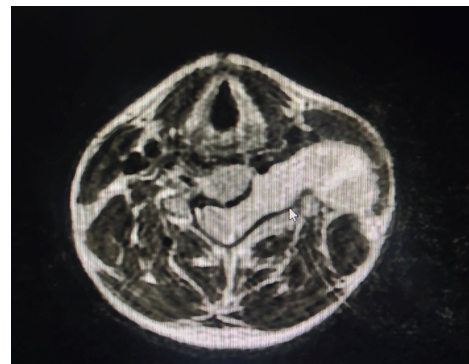


Fig 3. Axial section of MRI image

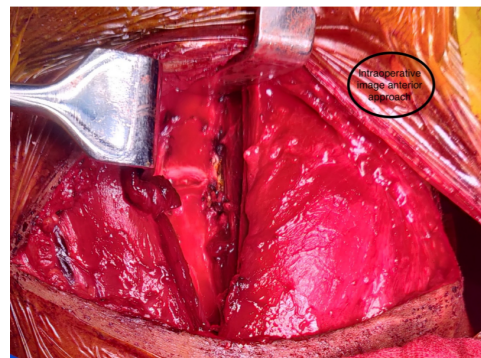


Fig 4. Intraoperative image anterior approach

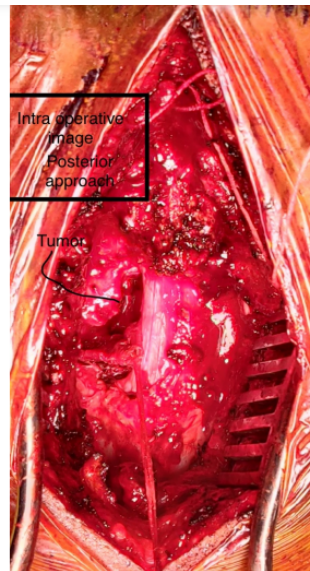


Fig 5. Intraoperative image posterior approach

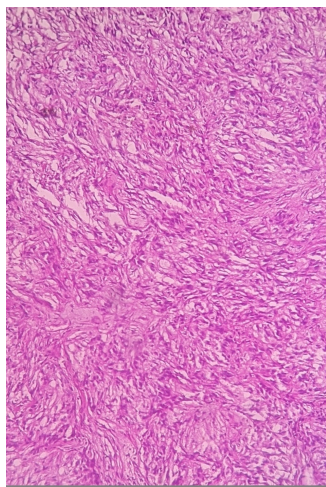


Fig 6. Histopathology showing fibroblastic meningioma

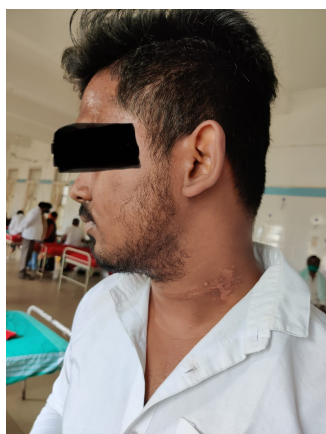

Fig 7. Anterior approach scar

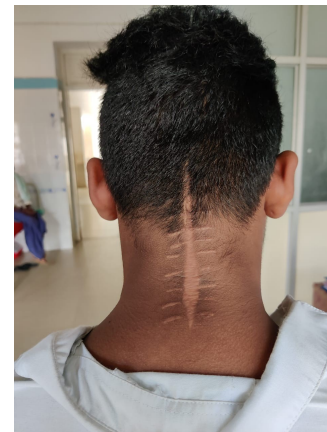

Fig 8. Posterior approach scar

Discussion

Meningiomas are benign slow growing tumors arising in intracranial, intraspinal or orbital locations. The intraventricular and epidural localizations are uncommon. Intraspinal meningiomas have a predilection to localize in the thoracic region located intradural extramedullary, being most likely derived from the meningotheial cells of the arachnoid layer. They are rarely found in an extradural location, that may be explained by the following hypotheses: (I) by proliferation of ectopic arachnoidal cells around the periradicular nerve root sleeves; or (II) by the displacement of the primitive embryonic remnants of the arachnoid mater and villi along the periradicular dura; or (III) by the migration of islands of arachnoid tissue into the extradural space^(3,4).

These are generally slow growing tumours manifesting in the fourth to fifth decade, with a predilection for women. They rarely cause clinical symptoms at an earlier age⁽⁵⁾. The symptomatology of meningiomas includes neurological signs and symptoms due to compression of adjacent structures; the specific deficits depend on tumour location. Spinal meningiomas present with pain, motor and sensory changes with sphincter disturbances.

MRI is recommended for the diagnosis of spinal meningiomas. In extradural spinal lesions, the differentials included are: metastatic lesions, schwannoma, neurofibroma, chordomas, synovial cyst, infectious etiology and meningioma. MRI of spinal meningiomas on T1W images exhibit signal intensity similar to that of spinal cord and does not show significant increased signal intensity on T2W images. However, contrast enhancement is immediate and homogeneous⁽⁵⁾. Radiological features revealing lack of foraminal extension suggests a diagnosis of meningioma over schwannoma or neurofibromas. The latter two tumours demonstrate high signal intensity on T2W images, cystic changes with homogeneous enhancement⁽⁶⁾. Chordoma is isotense to marrow on a T1W image while synovial cyst is contiguous to the joint, is spherical and

measures approximately 1–2 cm⁽⁷⁾.

Histopathology of spinal meningiomas usually exhibits meningotheelial, fibroblastic, transitional and psammomatous patterns. In most of the case reports, meningotheelial and psammomatous variants have been described (Table 1).

Meningioma is a surgically-treated disease. The best therapeutic approach for these tumours is the total removal of the tumour, whereas adjuvant radiotherapy after resection of atypical (WHO grade II) or malignant (WHO grade III) meningiomas should be considered. The major prognostic factors regarding WHO grade II and grade III meningiomas are estimates of recurrence and overall survival⁽⁸⁾. The major clinical factor in recurrence is the extent of resection which is invariably influenced by tumour site, extent of invasion and attachment to vital intracranial/intraspinal structures. In terms of histopathology, some variants are more likely to recur. The most useful morphological predictor of recurrence is the overall WHO grade. Benign meningiomas have recurrence rates of approximately 7–25%, atypical meningiomas show recurrence rates of 29–52% and anaplastic meningiomas recur in 50–94% of cases⁽⁹⁾. Meningiomas with malignant histological features are associated with shorter survival times; approximately 2–5 years depending largely on the extent of resection⁽¹⁰⁾.

In current patient, he underwent excision twice for the swelling which was clinically misdiagnosed for common neck swellings, which is lymph node swelling. Later on, patient came with recurrence for which USG and MRI done with a probable diagnosis of intradural extramedullary peripheral nerve sheath tumor. Intraoperatively extradural greyish mass was splaying/adherent over C5 nerve root and near total excision of tumor done with histopathology report showed fibroblastic meningioma (WHO GRADE1).

Conclusion

Extradural meningiomas are very rare lesions. To the best of our knowledge, only ten cases have been reported to date. Although simple to diagnose on histopathology, meningiomas at unusual sites can pose a preoperative radiologic

dilemma, as the radiologic findings overlap with more common extradural spinal masses like peripheral nerve sheath tumors or metastatic lesions. Surgery is the only effective treatment, and its goal should be the radical resection of the lesion to avoid recurrence. When radical resection of tumor poses a risk, however, subtotal resection can be a wise option.

References

- 1) Nsir AB, Boughamouira M, Mahmoudi H, Kilani M, Hattab N. Uncommon Progression of an Extradural Spinal Meningioma. *Case Reports in Surgery*. 2014;2014:1–4. Available from: <https://dx.doi.org/10.1155/2014/630876>.
- 2) Pant I, Gautam VKS, Kumari R, Chaturvedi S. Spinal tumour: primary cervical extradural meningioma at an unusual location. *Journal of Spine Surgery*. 2017;3(3):509–513. Available from: <https://dx.doi.org/10.21037/jss.2017.08.11>.
- 3) Zevgaridis D, Thomé C. Purely epidural spinal meningioma mimicking metastatic tumor: case report and review of the literature. *Spine (Phila Pa 1976)*. 2002;27(18):E403–5. Available from: [10.1097/00007632-200209150-00021](https://doi.org/10.1097/00007632-200209150-00021).
- 4) Tuli J, Drzymalski DM, Lidov H, Tuli S. Extradural En-Plaque Spinal Meningioma with Intraneural Invasion. *World Neurosurgery*. 2012;77(202):e5–e13. Available from: <https://dx.doi.org/10.1016/j.wneu.2011.03.047>.
- 5) Gambardella G, Toscano S, Staropoli C, Longo M, D'Amico D, Marafioti T, et al. Epidural spinal meningioma. Role of magnetic resonance in differential diagnosis. *Acta Neurochirurgica*. 1990;107(1-2):70–73. Available from: <https://dx.doi.org/10.1007/bf01402617>.
- 6) Khamary SME, Alorainy IA. Case 100: Spinal Epidural Meningioma. *Radiology*. 2006;241(2):614–617. Available from: <https://dx.doi.org/10.1148/radiol.2412040203>.
- 7) Ross J, Brant-Zawadzki M, Chen M, Moore K, Salzman K. *Diagnostic Imaging: Spine*. 1st ed.. 2004.
- 8) Jääskeläinen J. Seemingly complete removal of histologically benign intracranial meningioma: Late recurrence rate and factors predicting recurrence in 657 patients. A multivariate analysis. *Surgical Neurology*. 1986;26(5):461–469. Available from: [https://dx.doi.org/10.1016/0090-3019\(86\)90259-4](https://dx.doi.org/10.1016/0090-3019(86)90259-4).
- 9) Marciscano AE, Stemmer-Rachamimov AO, Niemierko A, Larvie M, Curry WT, Barker FG, et al. Benign meningiomas (WHO Grade I) with atypical histological features: correlation of histopathological features with clinical outcomes. *Journal of Neurosurgery*. 2016;124(1):106–114. Available from: <https://dx.doi.org/10.3171/2015.1.jns142228>.
- 10) Aizer AA, Bi WL, Kandola MS, Lee EQ, Nayak L, Rinne ML, et al. Extent of resection and overall survival for patients with atypical and malignant meningioma. *Cancer*. 2015;121(24):4376–4381. Available from: <https://dx.doi.org/10.1002/cncr.29639>.

Table 1. Summary of spinal extradural meningioma reported till date

Number	Age (years)	Sex	Site	Treatment	Extent of resection	Histopathologic variant	Author reference
1	76	Female	Thoracic spine (T6-T7)	T6 Hemilaminectomy	Complete excision	Meningothelial	Buchfelder et al.[2001]
2	58	Male	Thoracic spine (T10-T12)	T11-T12 Hemilaminectomy	Complete excision	Fibroblastic	Suzuki A et al.[2002]
3	57	Female	Cervicothoracic spine (C7-T2)	Total laminectomy+ adjuvant RT	Complete excision	Psammomatous meningioma with infiltration	Restrep et al.[2006]
4	42	Male	Thoracic spine (T2-T3)	T2-T3 Laminectomy	Complete excision	Psammomatous	Santiago et al.[2009]
5	41	Male	Cervical Spine (C3-C7)	C3-C7 Laminectomy	Complete excision	Meningothelial	Bettaswamy et al. [2011]
6	50	Male	Thoracic spine (T6-T7)	T6 Hemilaminectomy	Complete excision	Meningothelial	Kim et al. [2011]
7	45	Female	Thoracic spine (T9-T10)	T9-T10 laminectomy	Complete excision	Psammomatous	Shresth et al.[2012]
8	48	Female	Cervicothoracic spine (C7-T2)	T1 Total Laminectomy	Complete excision	Psammomatous	Yaldiz et al.[2014]
9	50	Male	Cervical spine (C2-C4)	C2-C4 Laminectomy	Near total excision	Meningothelial	Bettaswamy et al. [2015]
10	50	Male	Cervical spine (C5-C7)	C3-C6 Laminectomy	Near total excision	Meningothelial	Pant et al [2017] ⁽²⁾
11	18	Male	Cervical spine (C4-C6)	C4-C5 Laminectomy	Near total excision	Fibroblastic	Our case