


CASE REPORT



Received: 14.02.2021

Accepted: 31.03.2021

Published: 06.04.2021

Citation: Vishnu Sharma M, Harikumar L. (2021). Tale of a foreign body. International Journal of Preclinical & Clinical Research. 2(1): 18-19. <https://doi.org/10.51131/IJPCCR/v2i1.9>

* **Corresponding author.**

drvishnusharmag@gmail.com

Funding: None

Competing Interests: None

Copyright: © 2021 Vishnu Sharma & Harikumar. This is an open access article distributed under the terms of the [Creative Commons Attribution License](#), which permits unrestricted use, distribution, and reproduction in any medium, provided the original author and source are credited.

Published By Basaveshwara Medical College & Hospital, Chitradurga, Karnataka

ISSN

Print: XXXX-XXXX

Electronic: XXXX-XXXX

Tale of a foreign body

M Vishnu Sharma^{1*}, Lakshmi Harikumar²

1 Professor and Head, Department of respiratory medicine, A.J. Institute of medical sciences and Research centre, Kuntikana, Mangalore, Karnataka

2 Postgraduate resident, Department of Respiratory medicine, A. J. Institute of medical sciences & Research center, Kuntikana, Mangalore, Karnataka, India

Abstract

Aspiration of a tooth is often overlooked in patients with road traffic accidents. Patients with facial trauma can have avulsion of teeth, which may be then aspirated. It can lead to immediate complication — airway obstruction and hypoxia which may sometimes be fatal. Delayed complications are mainly due to airway obstruction leading to chronic respiratory symptoms and recurrent respiratory infections. Hence, aspirated foreign body should be promptly recognised and should be removed. We aim to highlight this in this case report.

Keywords: Aspiration; teeth; road traffic accident; risk factors; complications

Introduction

Failure to recognise chest radiological abnormalities in preoperative chest X-ray can lead to post-operative complications and also may lead to litigations. One should be aware of the radiological abnormalities encountered in different clinical conditions. We describe an aspirated foreign body in a patient following a road traffic accident where the patient did not have any symptoms or signs. In the absence of symptoms or signs, an aspirated foreign body can be missed if proper attention is not paid to the chest radiograph.

Case report

A 26-years-old patient was admitted with a head injury following a road traffic accident. Chest X-ray was taken for preoperative evaluation as he required an emer-

gency craniotomy. He had no external injuries on the chest. He had no respiratory symptoms. He had no history of any lung disease. Clinical examination of the respiratory system was normal. He had a lacerated wound in the upper lip on the right side. What is the radiological abnormality?

Careful evaluation of the chest X-ray shows an opacity in the right lower zone, the shape of which is characteristic of a tooth ([Figure 1](#)). Oral cavity examination showed loss of right upper canine teeth due to the trauma.

Discussion

Road traffic accidents can lead to aspiration. Decreased level of consciousness, facial trauma, head injury, polytrauma, full stomach, alcohol intake, repeated vomiting, presence of dentures and loose

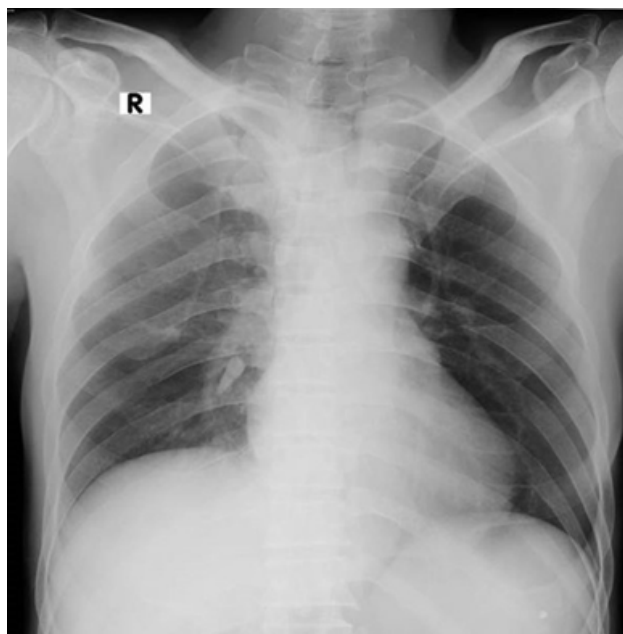


Fig 1. X-ray radiograph

teeth are the important risk factors for aspiration following road traffic accident.⁽¹⁾

It should be remembered that facial trauma can be associated with the avulsion of teeth. This avulsed tooth can be aspirated either spontaneously or during emergency intubation.⁽²⁾ Patients with a decreased level of consciousness are at higher risk for spontaneous aspiration. Hence, all patients with a history of facial trauma should have a proper oro-dental examination and if any missing teeth are noticed, a careful clinical and radiological examination should be done to rule out aspiration even in the absence of symptoms.

Aspiration of a tooth accounts for 0.4% of all foreign bodies.⁽²⁾ Aspirated teeth can lead to complications if not diagnosed and treated promptly. Immediate complications include respiratory distress due to major airway obstruction, laryngeal oedema due to trauma from a sharp tooth.⁽²⁾ Rarely pneumothorax can occur as a complication when sharp teeth or rather a piece of teeth migrates to the lung periphery to pierce the visceral pleural. Late complications include chronic cough, recurrent lower respiratory tract infection, lung abscess, recurrent or unresolving pneumonia, collapse of a lobe or segment of lung, and bronchiectasis.⁽³⁾ Rarely some patients may present with chronic cough and asthma like symptoms.⁽⁴⁾ All these complications are due to bronchial

obstruction.

Aspiration of a foreign body into the respiratory tract can lead to immediate symptoms like choking, gagging, coughing, stridor, signs of respiratory distress, high-pitched localised wheezing, signs of collapse like reduced chest movement, tracheal shift, reduction or absence of air entry on the affected side^(5,6). Patients with road traffic accident may have multiple injuries. Hence, these patients may not have any symptoms or signs of aspiration or these may be overlooked due to other serious injuries.

Foreign bodies in the respiratory tract should be removed to prevent further complications. Before removal, the type, size and location of the foreign body should be determined by proper history, physical examination and chest X-ray⁽⁶⁾. Careful examination of chest X-ray will reveal the presence of tooth in a majority of the cases of aspirated teeth. CT scan of the chest may be required in few cases. Either fibre optic or rigid bronchoscopy can be used for removal. Rarely surgical intervention may be required when bronchoscopy fails. In this patient, the tooth was removed by rigid bronchoscopy prior to surgery. He made uneventful recovery following craniotomy.

Conclusions

A careful oro-dental examination should be done in all patients with a history of facial trauma. Aspiration should be ruled out any missing teeth is noticed, even in the absence of symptoms/signs of aspiration.

References

- 1) Ottosson A. Aspiration and obstructed airways as the cause of death in 158 consecutive traffic fatalities. *The Journal of Trauma: Injury, Infection, and Critical Care*. 1985;25(6):538–540. doi:10.1097/00005373-198506000-00012.
- 2) Jillela S, Subrahmanyam R. Inhaled tooth in the bronchus: importance of early intervention. *British Journal of Anaesthesia*. 2015;115(2):318–319. doi:10.1093/bja/aev239.
- 3) Xiao WL, Zhang, Wang YH. Aspiration of two permanent teeth during maxillofacial injuries. *J Craniofac Surg*. 2009;20:558–60.
- 4) Yurdakul AS, Kanbay A, Kurul C, Yorgancilar D, Demircan S, Ekim N. An occult foreign body aspiration with bronchial anomaly mimicking asthma and pneumonia. *Dental Traumatology*. 2007;23(6):368–370. doi:10.1111/j.1600-9657.2006.00468.x.
- 5) Hisanaga R, Hagita K, Nojima K, Katakura A, Morinaga K, Ichinohe T, et al. Survey of accidental ingestion and aspiration at Tokyo dental college Chiba hospital. *The Bulletin of Tokyo Dental College*. 2010;51(2):95–101. doi:10.2209/tdcpublication.51.95.
- 6) Baharloo F, Veyckemans F, Francis C, Biethlot MP, Rodenstein DO. Tracheobronchial foreign bodies: Presentation and management in children and adults. *Chest*. 1999;115:1357–62.